

CASE 9

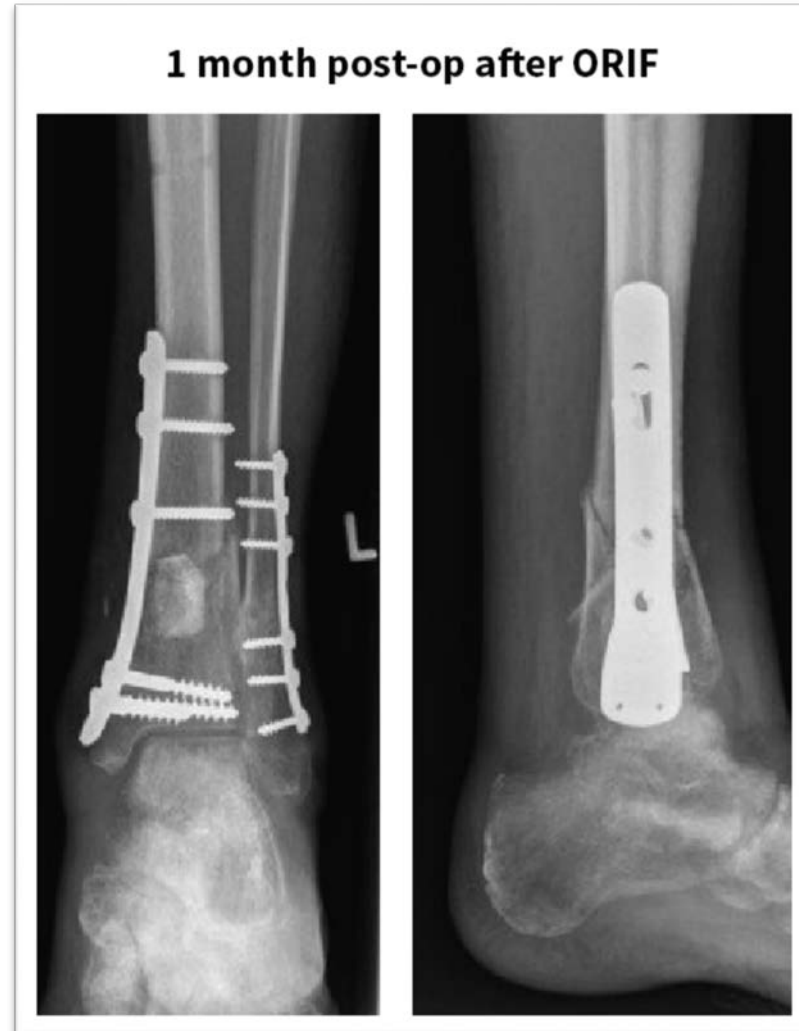**SEPTIC
NON-UNION IN
DISTAL TIBIA**

Courtesy of BG Unfallklinik Duisburg,
Germany

DISTAL TIBIA (CASE 9)

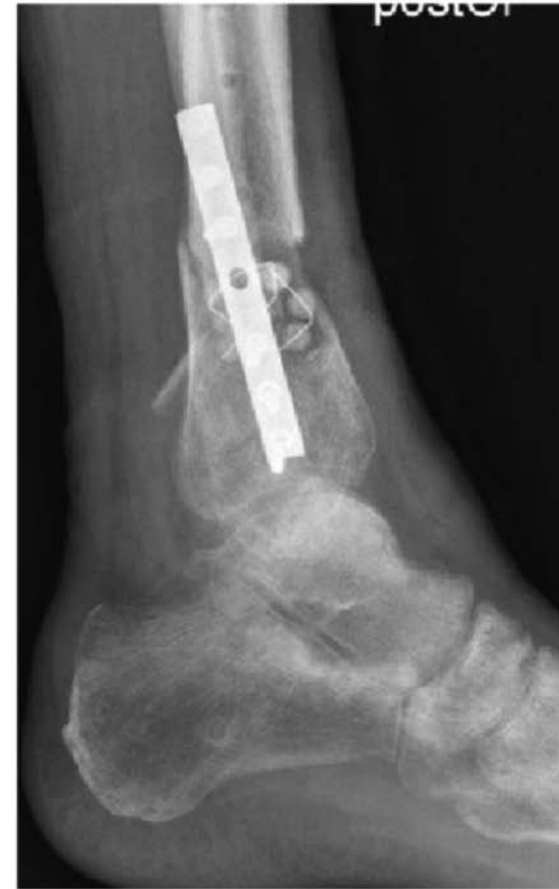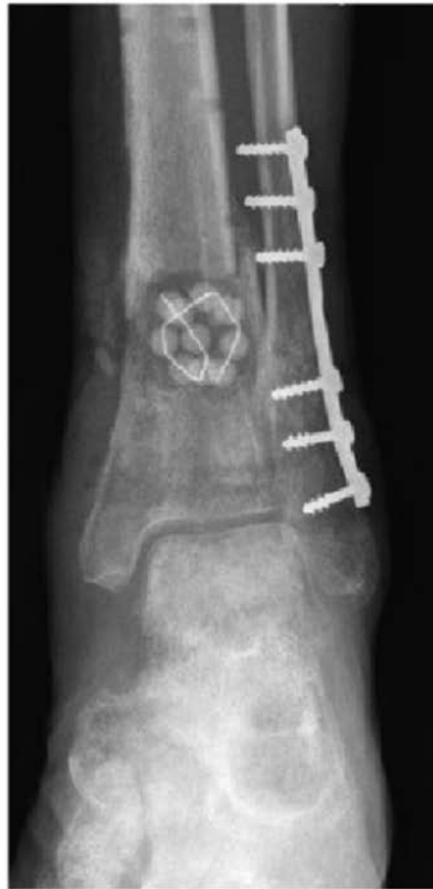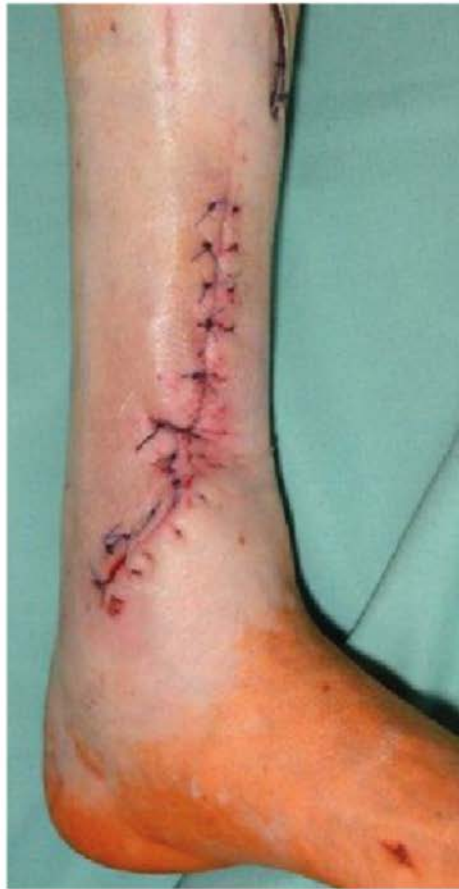- **Patient:** 61-year-old male.
- **Preoperative status:** Closed distal tibia fracture with affected Pilon tibiale. Infection of the tibial plate 3 months after Open Reduction Internal Fixation (ORIF).
- **Bacterial culture:** *Staphylococcus aureus* and *Staphylococcus epidermidis*

DISTAL TIBIA (CASE 9)



DISTAL TIBIA (CASE 9)

Revision surgery 3 months post-op due to infection

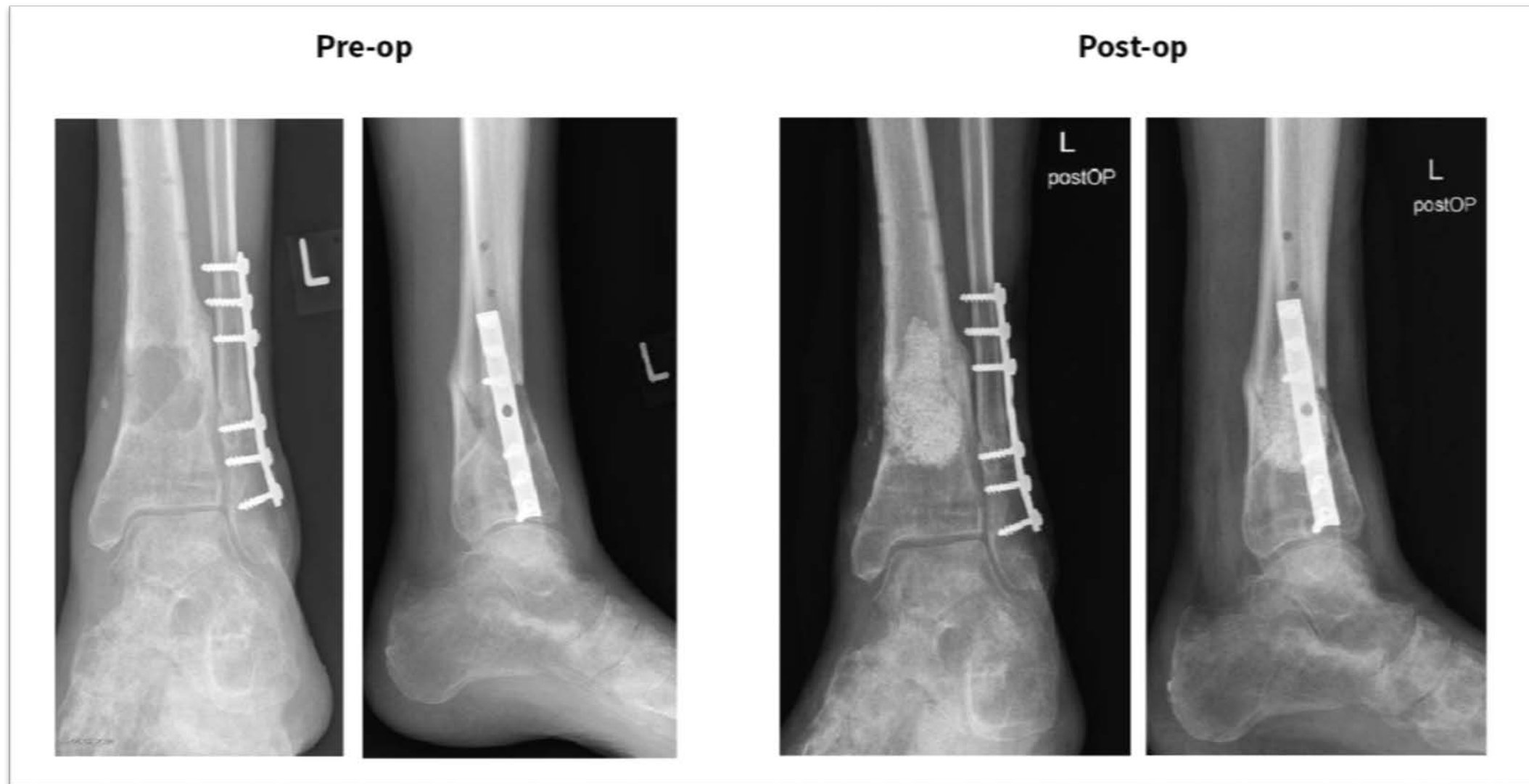


DISTAL TIBIA (CASE 9)

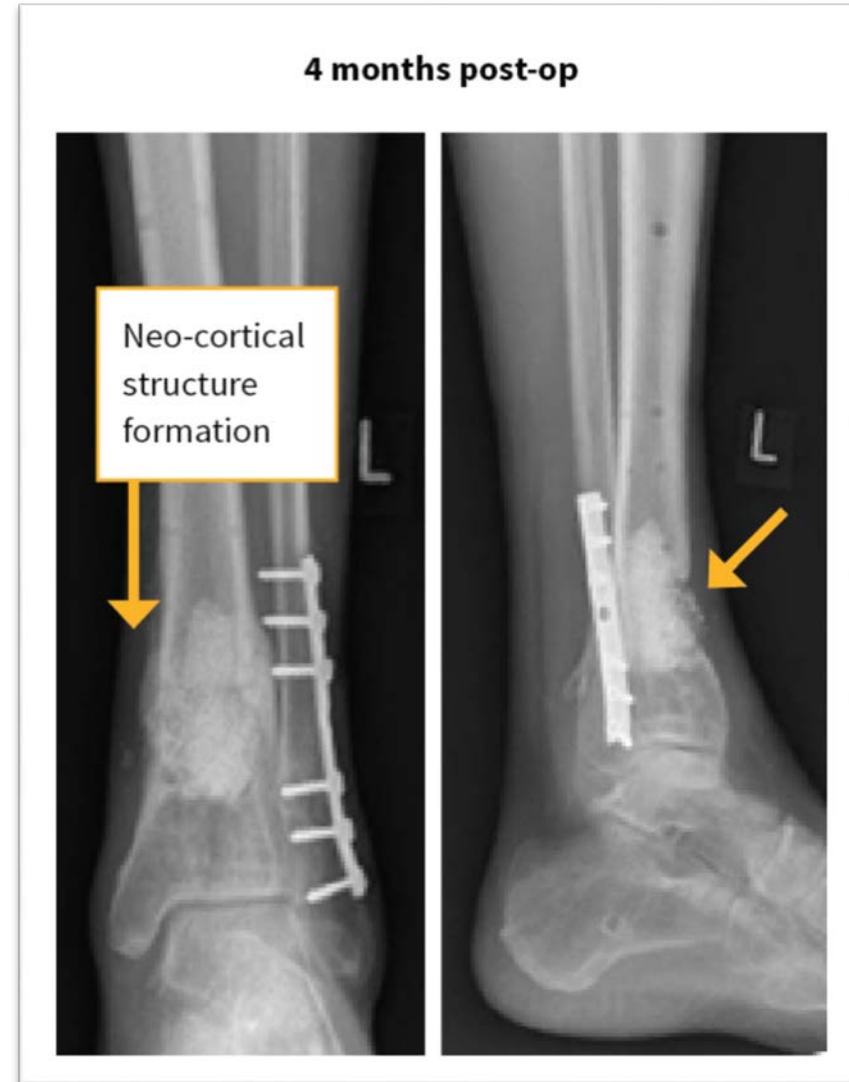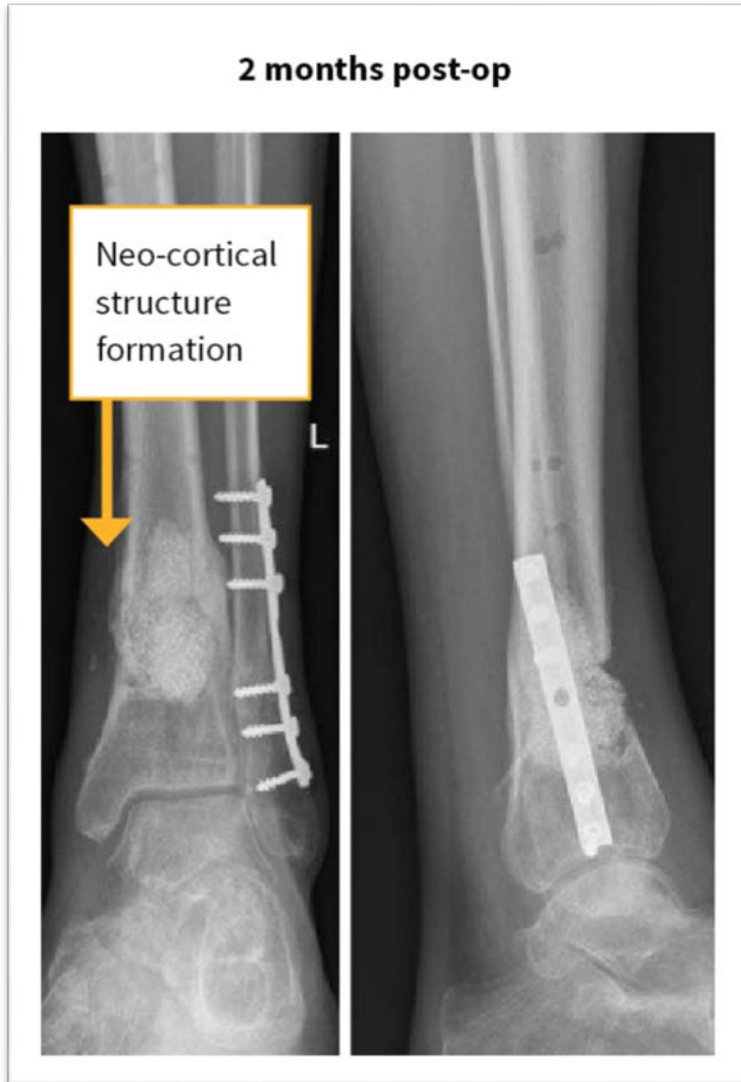- **Operation:** Removal of the antibiotic releasing beads after 6 weeks and implantation of 20 cc bioactive glass.

Bone formation can be observed 2 months and 4 months after treatment.

DISTAL TIBIA (CASE 9)

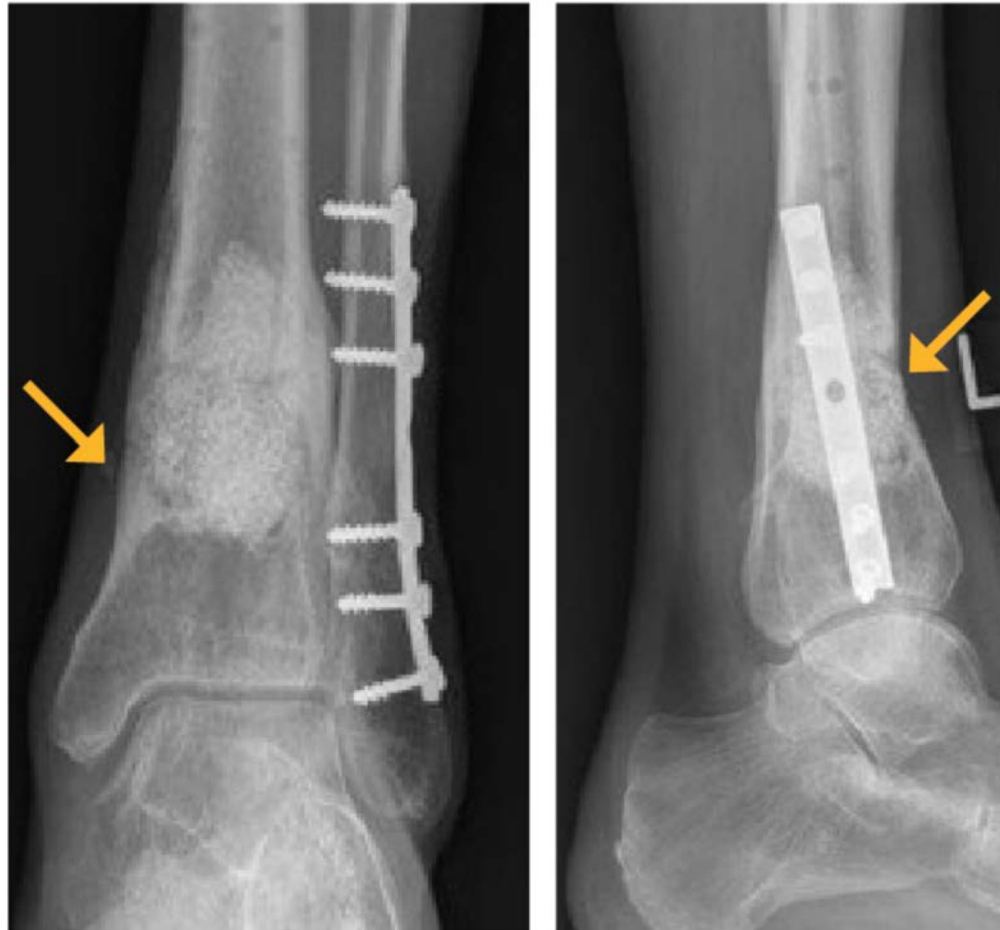


DISTAL TIBIA (CASE 9)



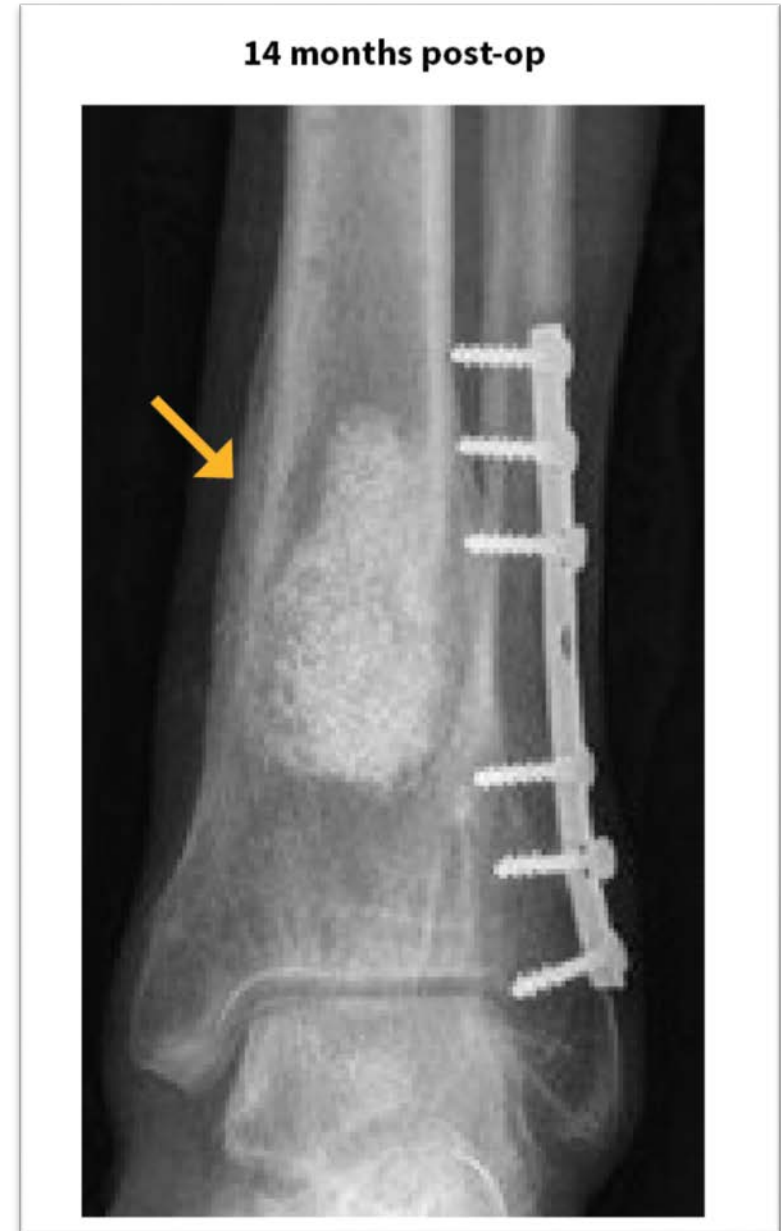DISTAL TIBIA (CASE 9)

8 months post-op



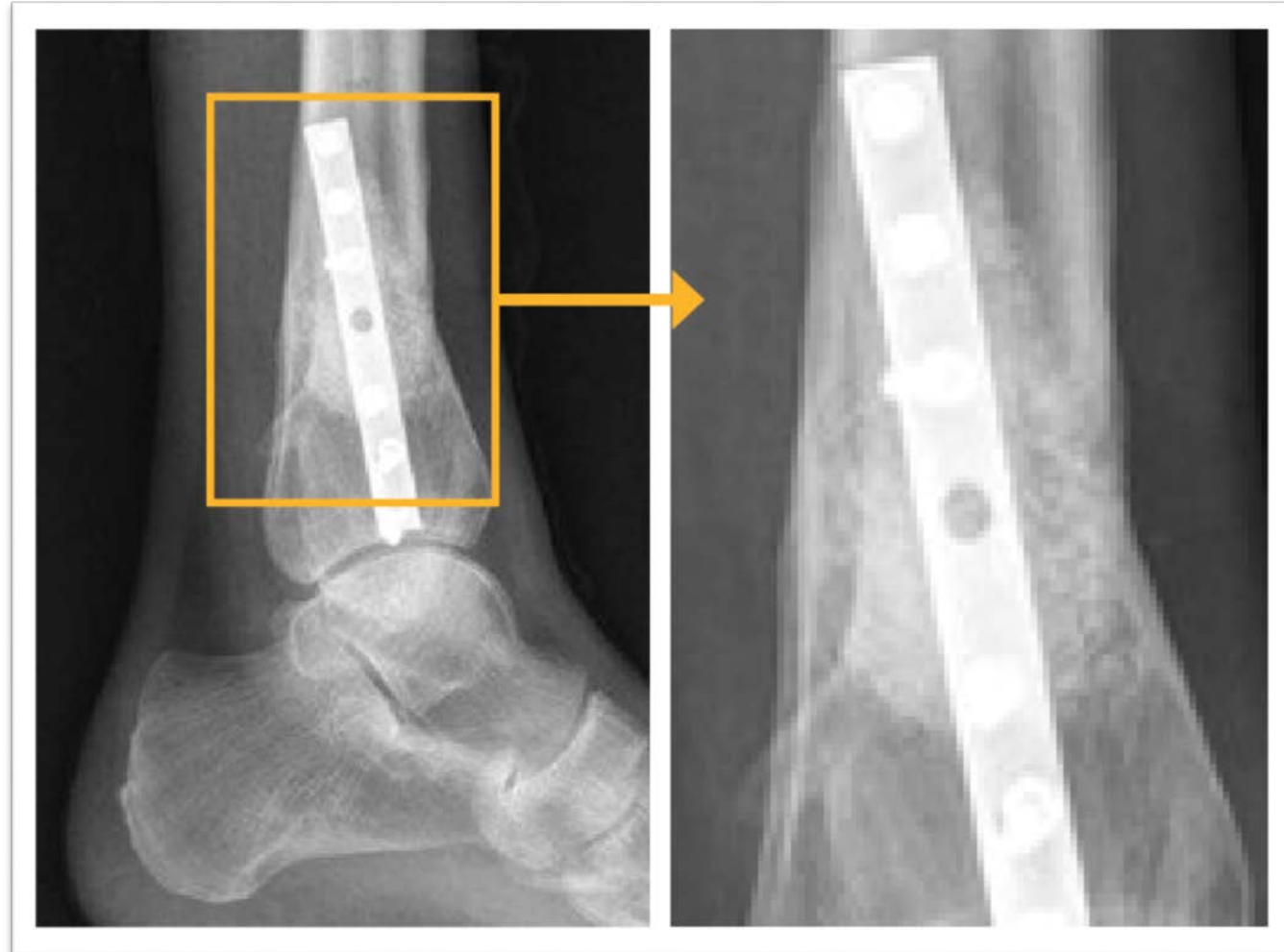
DISTAL TIBIA (CASE 9)

- **Final clinical outcome:** Periosteal reaction resembling a “neo-cortical-structure” is visible in the anterior region where bioactive glass has been implanted.



DISTAL TIBIA (CASE 9)

14 months post-op



DISTAL TIBIA (CASE 9)

