

CASE 6

**SEPTIC
NON-UNION IN
DISTAL TIBIA**

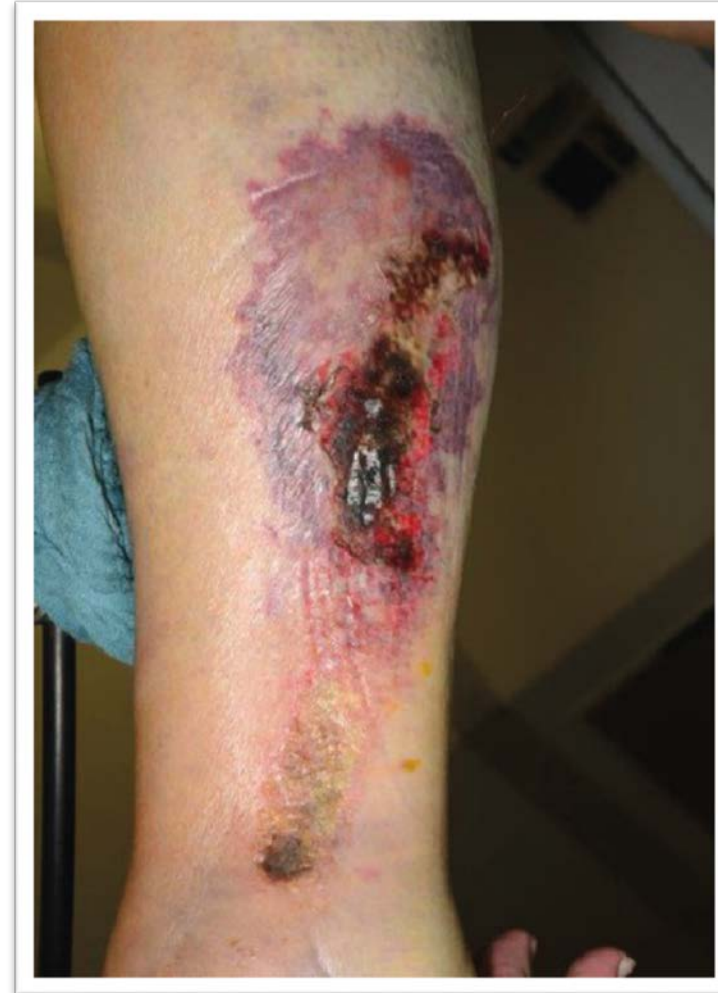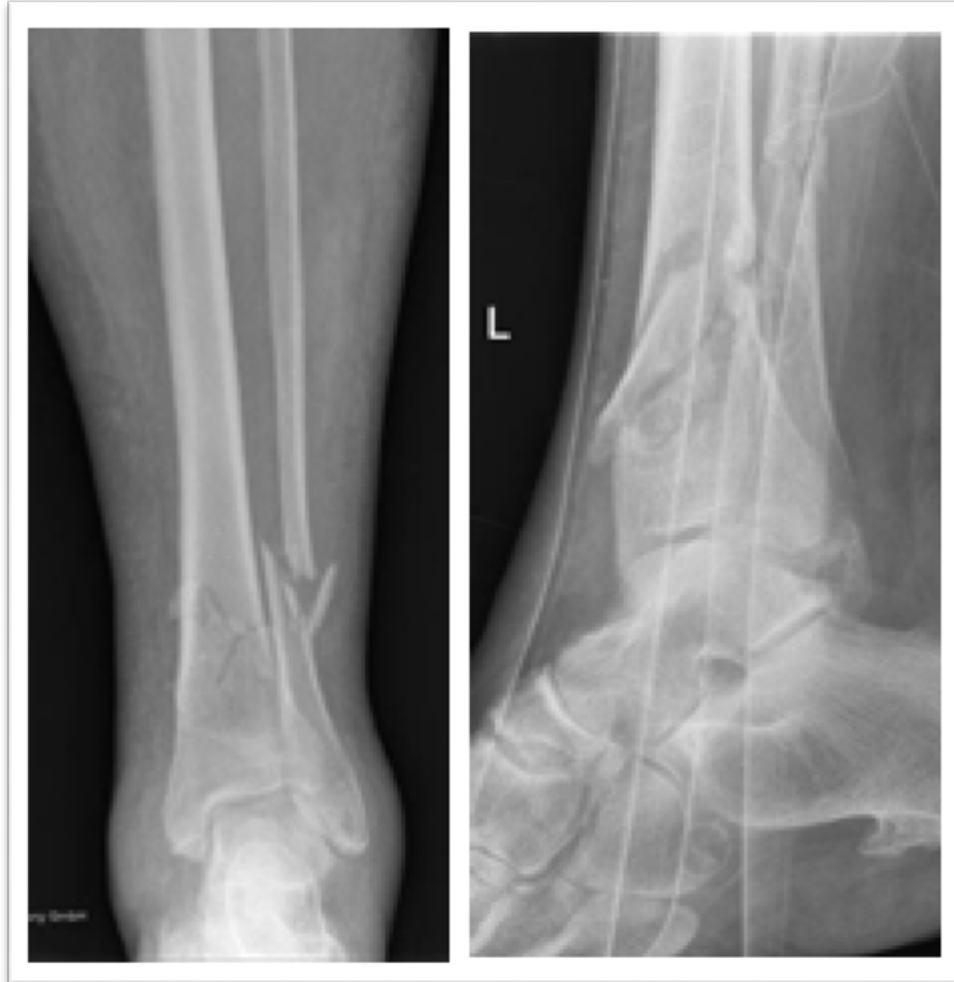Courtesy of BG Unfallklinik Duisburg,
Germany

DISTAL TIBIA (CASE 6)

- **Patient:** 79-year-old female
- **Preoperative status:** Closed tibial fracture in the distal diaphysis with the Pilon tibiale affected. Diagnosis of low grade tibial osteomyelitis 2 months after injury.
- **Bacterial culture:** multiresistant *Staphylococcus epidermidis*

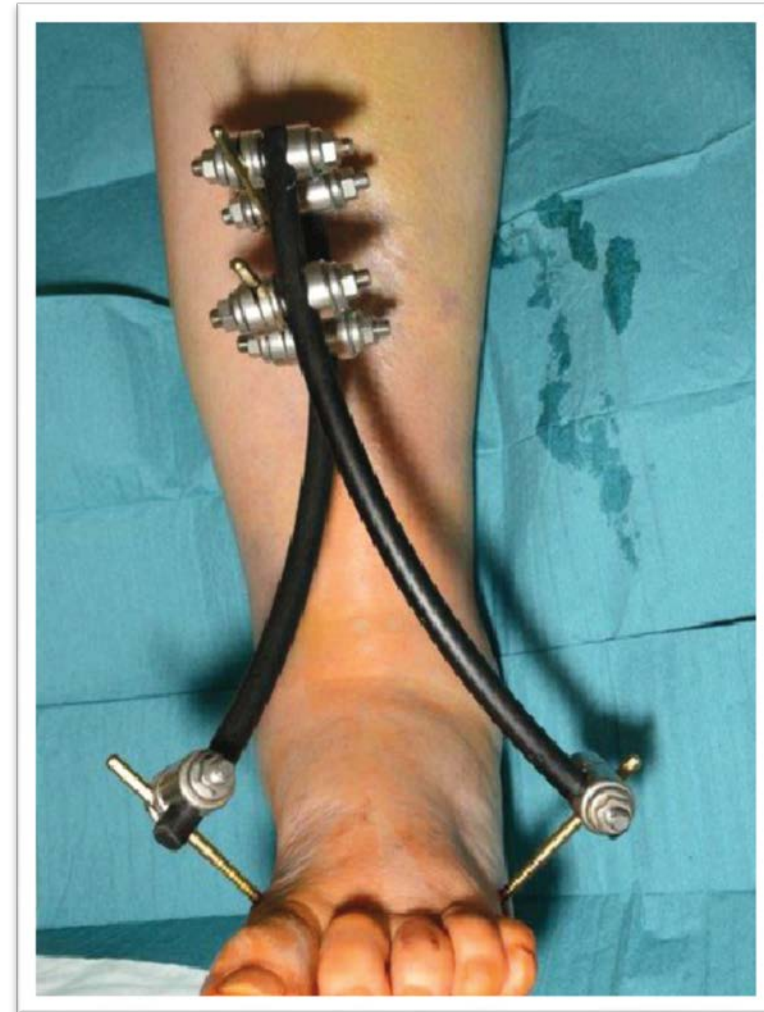
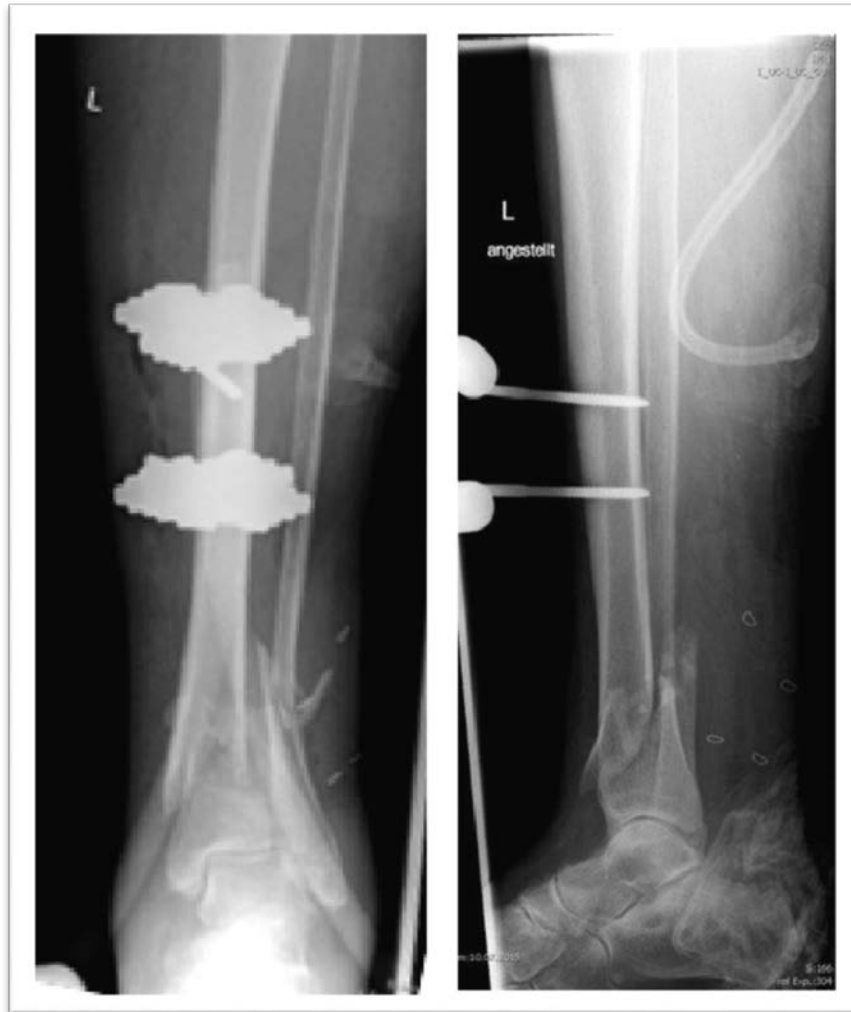DISTAL TIBIA (CASE 6)

Pre-op



DISTAL TIBIA (CASE 6)

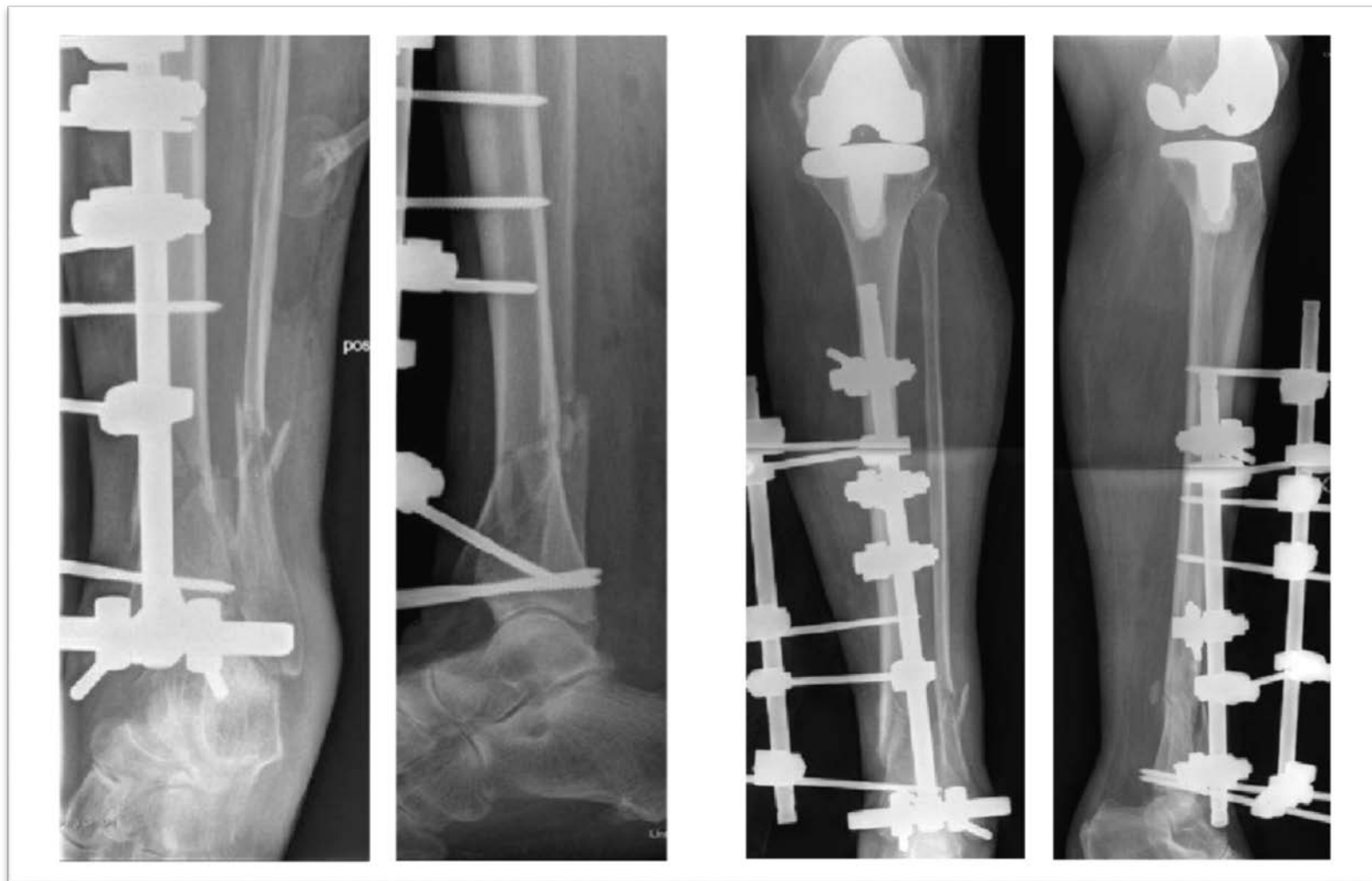Post-op



DISTAL TIBIA (CASE 6)

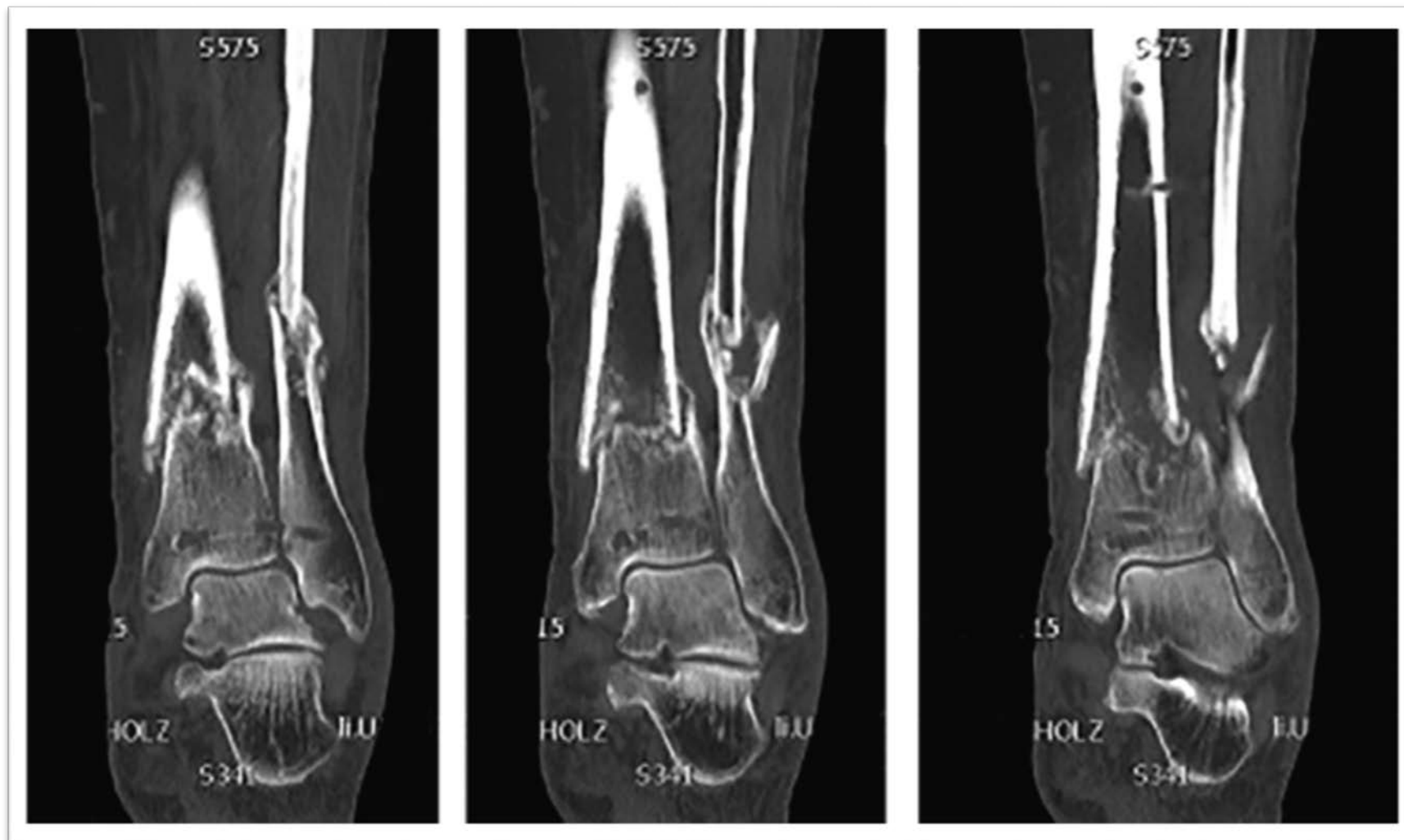
2 weeks post-op

8 weeks post-op



DISTAL TIBIA (CASE 6)

8 weeks post-op, Coronal (CT)

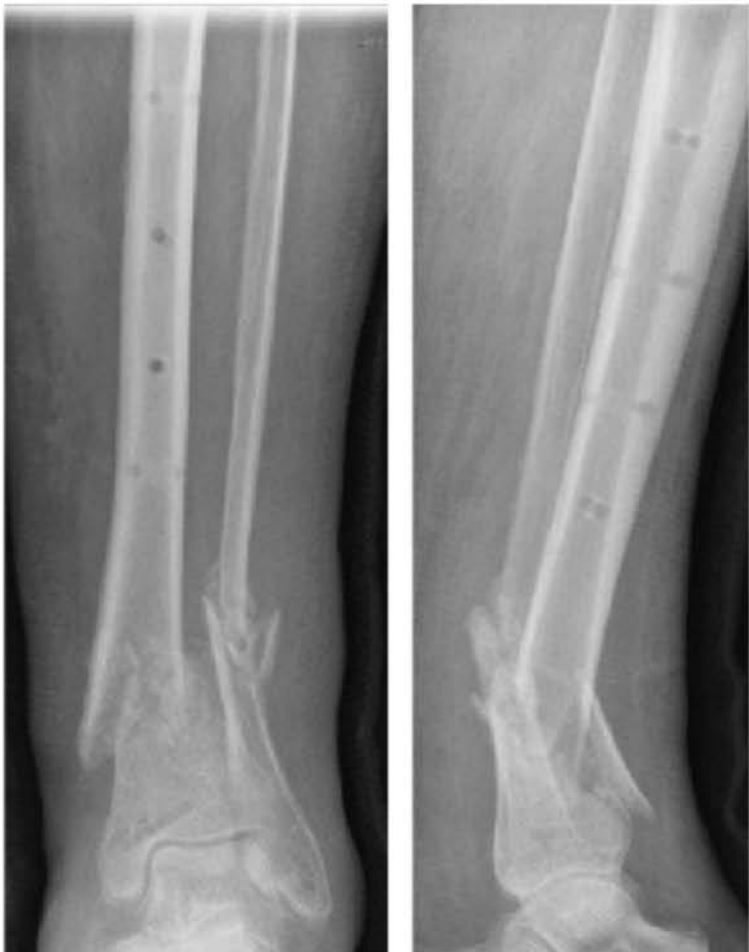

DISTAL TIBIA (CASE 6)

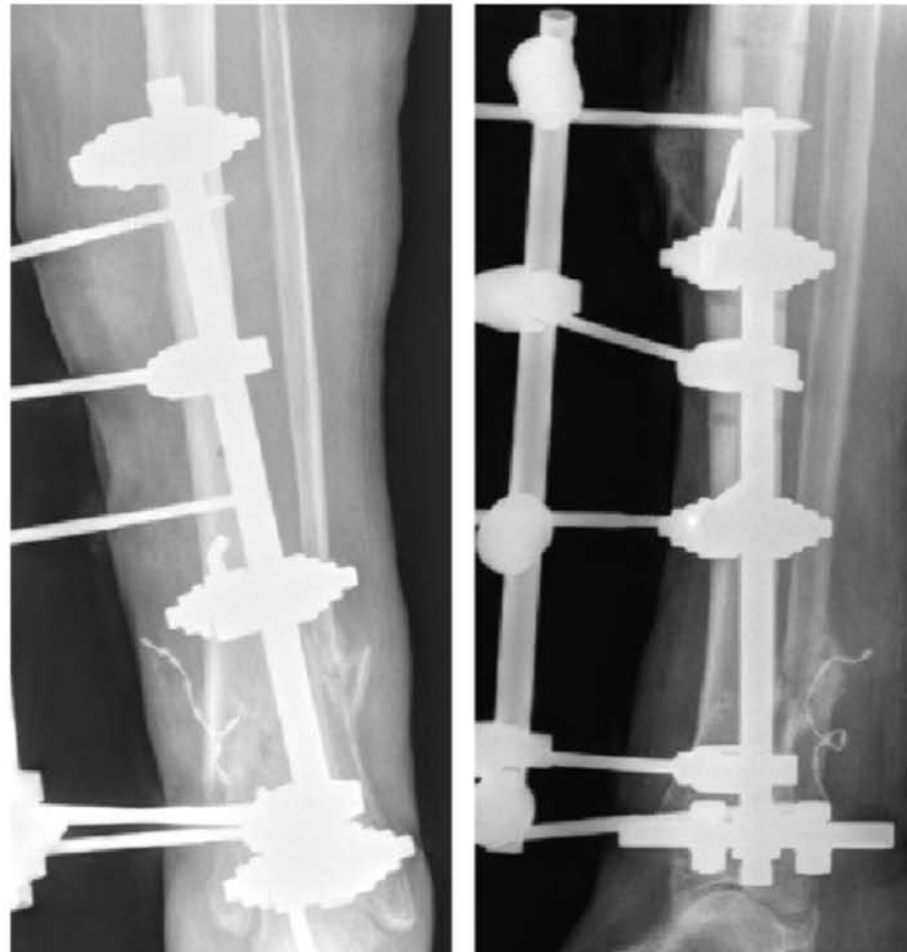
- **Operation:** Fixation and implantation of 20 cc bioactive glass 4 months post-op.

DISTAL TIBIA (CASE 6)

10 weeks post-op

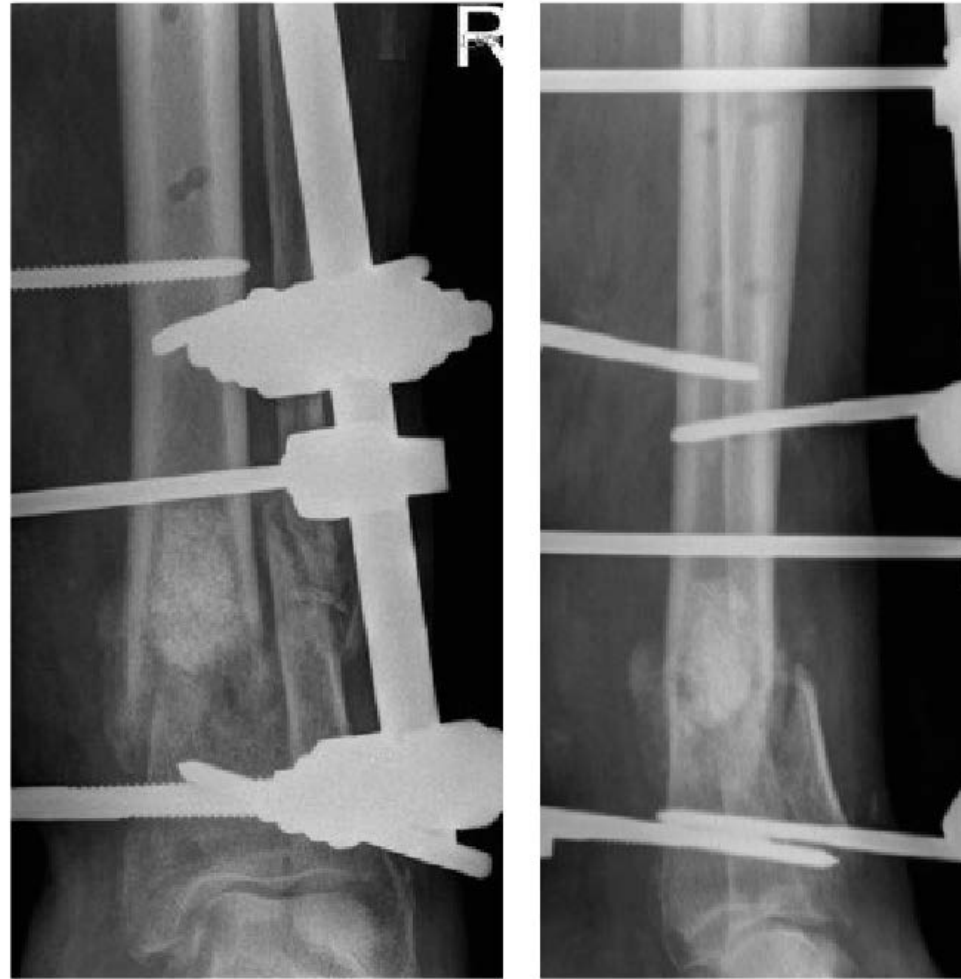

4 months post-op



DISTAL TIBIA (CASE 6)

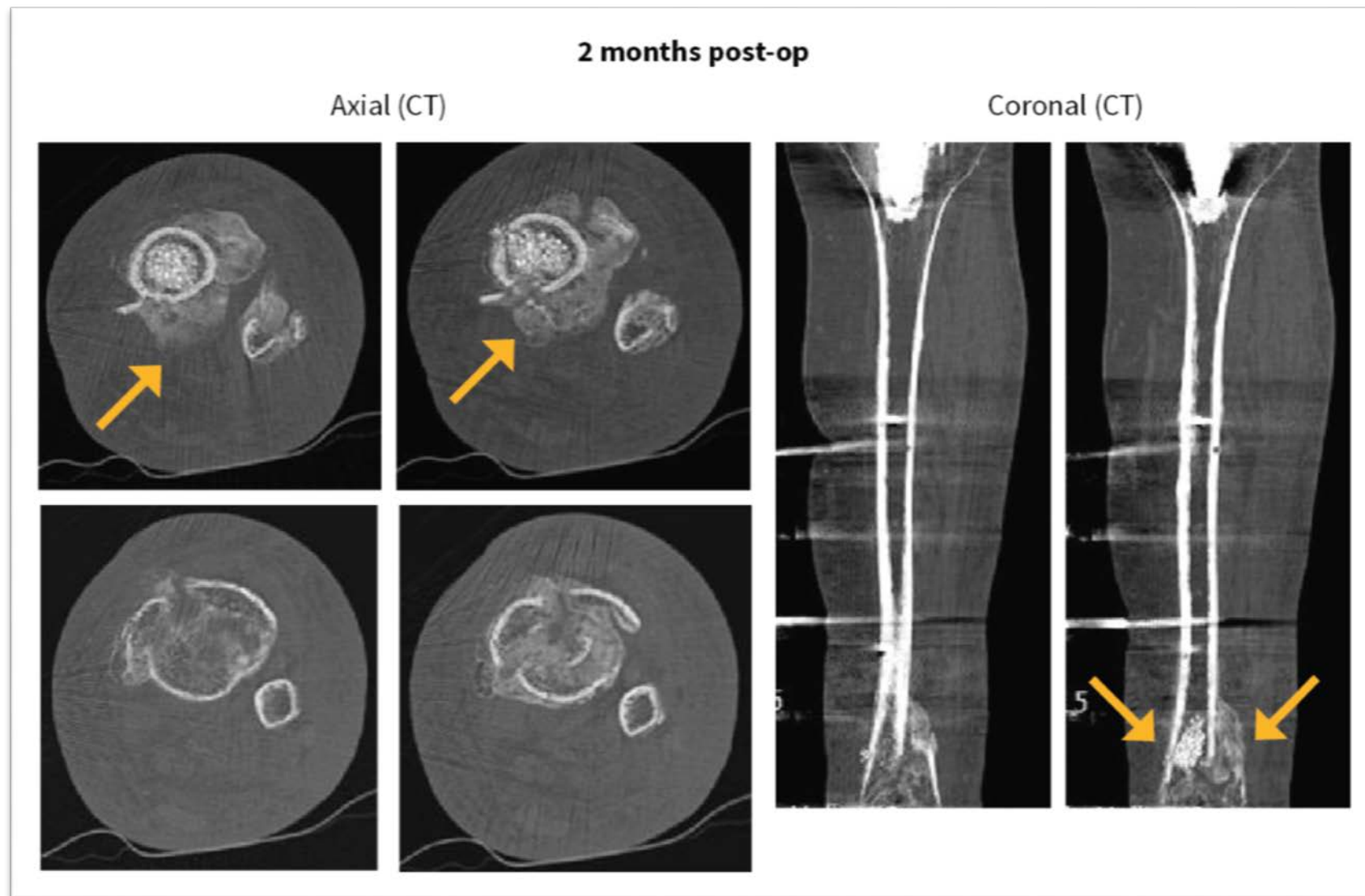
Post-op after bioactive glass implantation



DISTAL TIBIA (CASE 6)

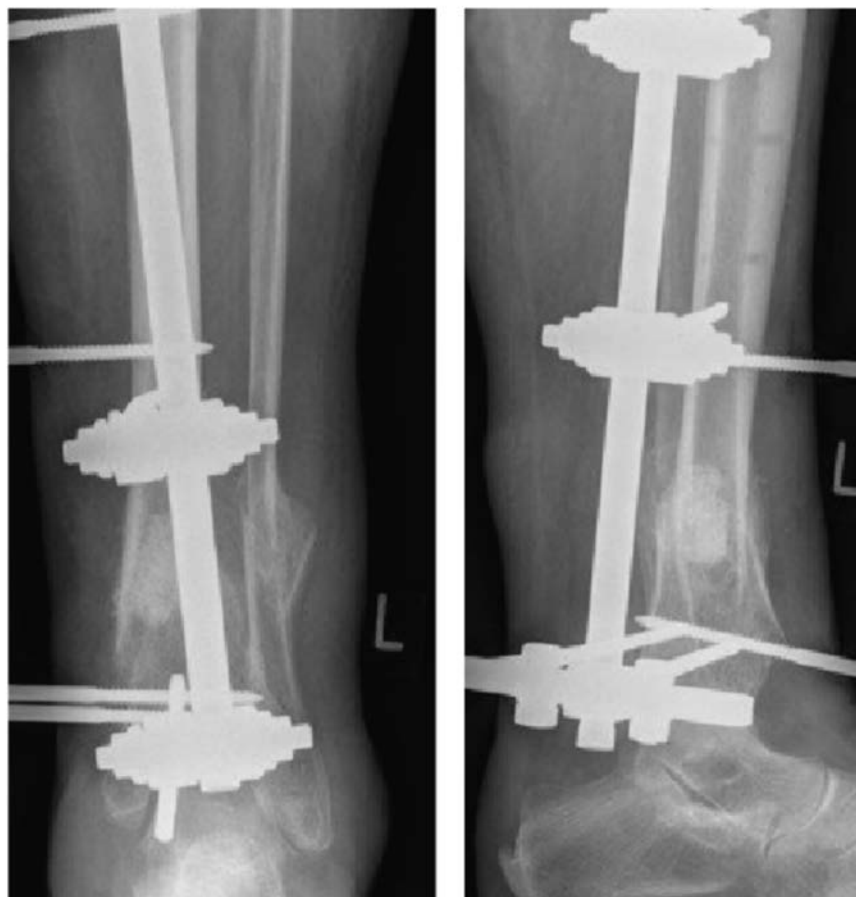- **Clinical outcome:** Increased bone formation 4 months after treatment, good bone healing and consolidation 7 months after treatment. Limb fully load bearing at 7 months.

DISTAL TIBIA (CASE 6)



DISTAL TIBIA (CASE 6)

4 months post-op



7 months post-op

